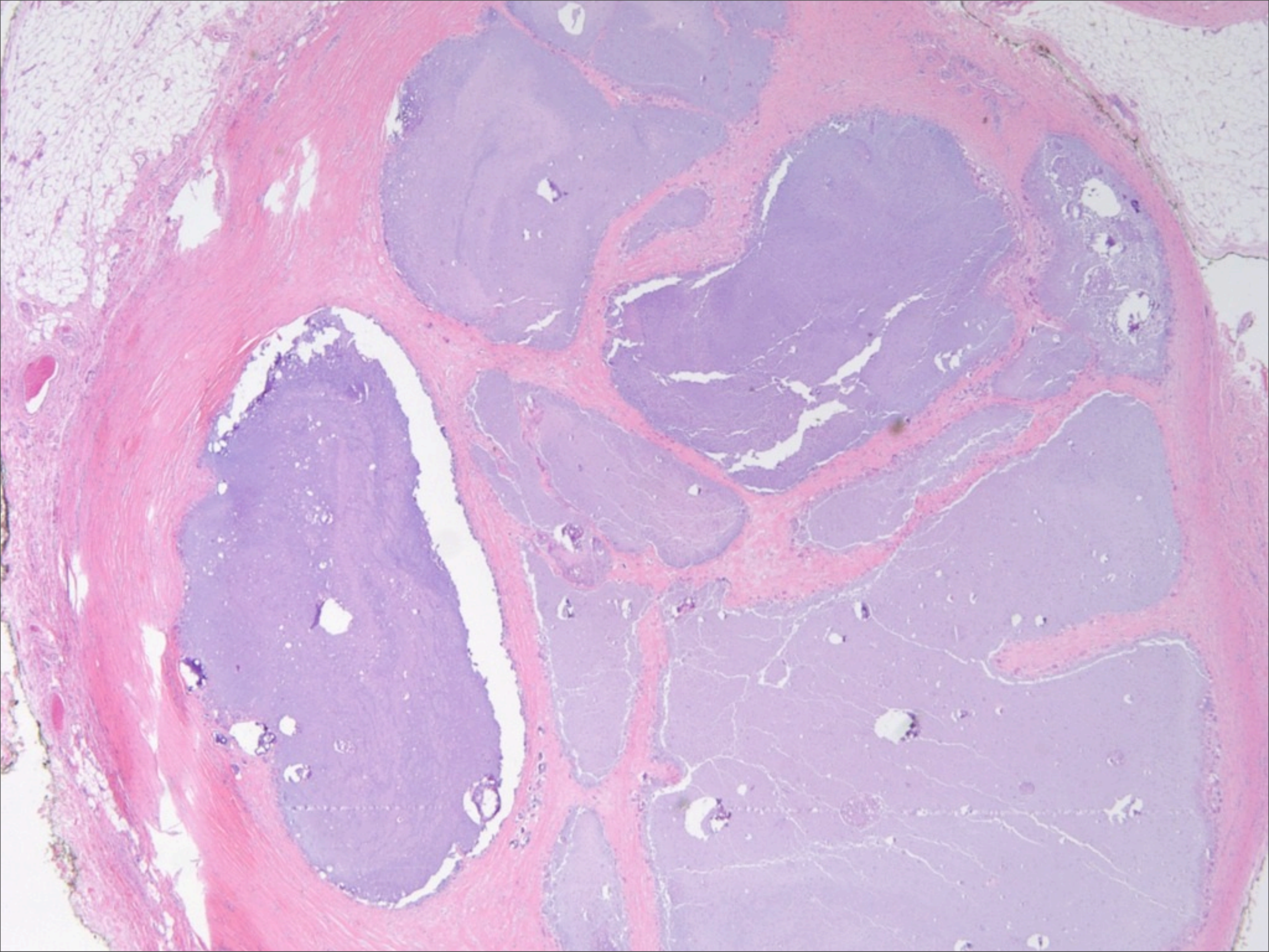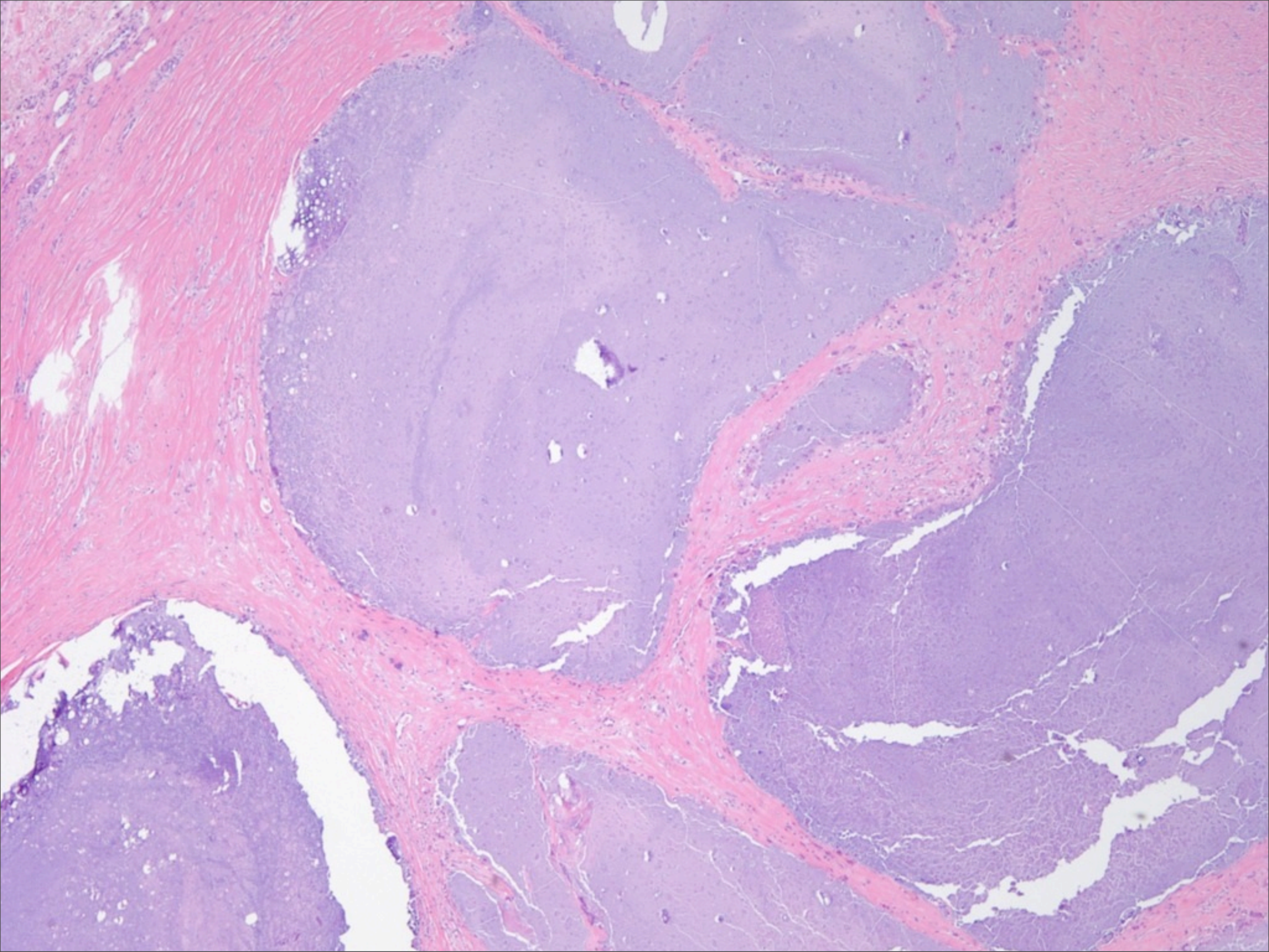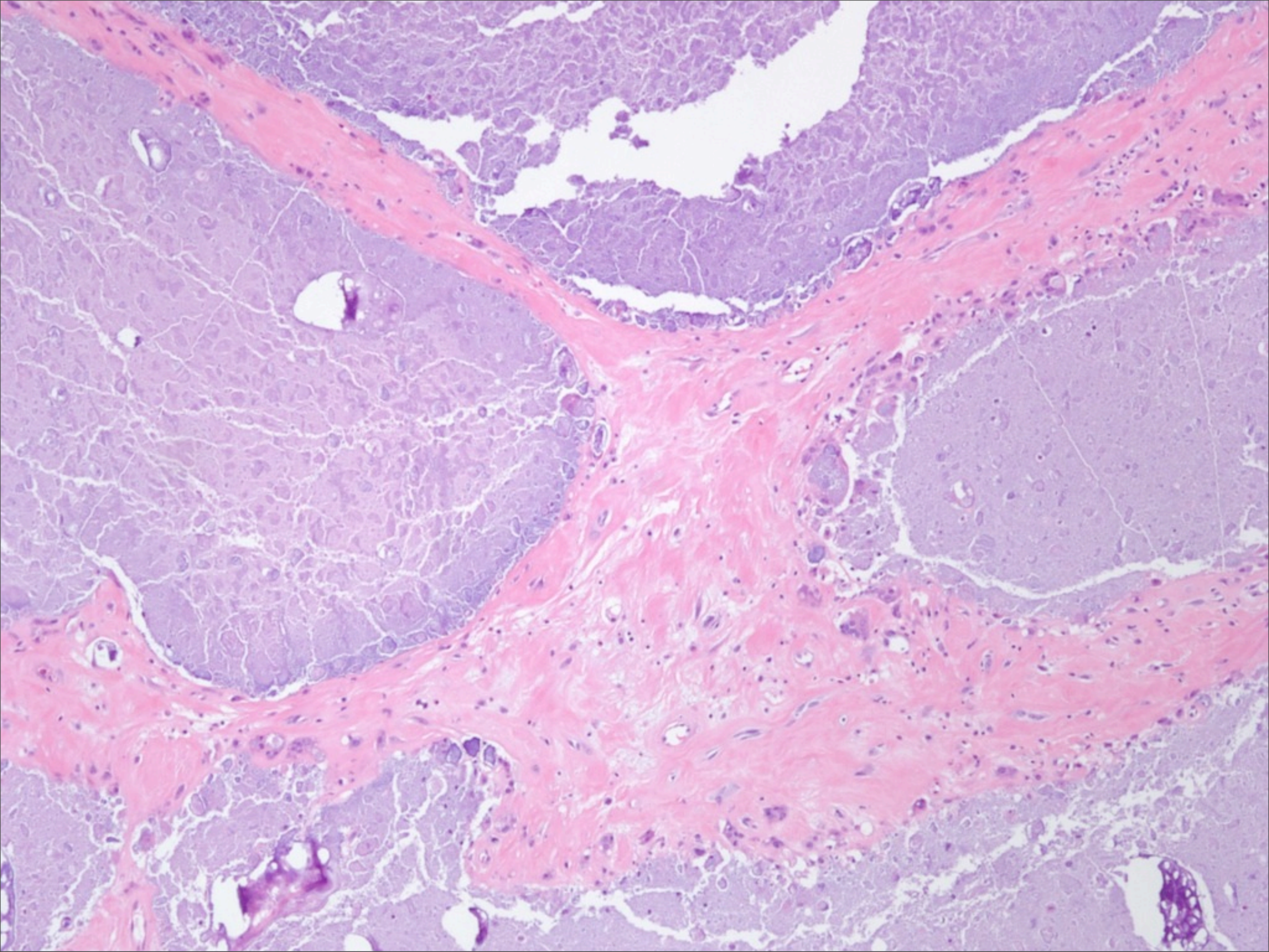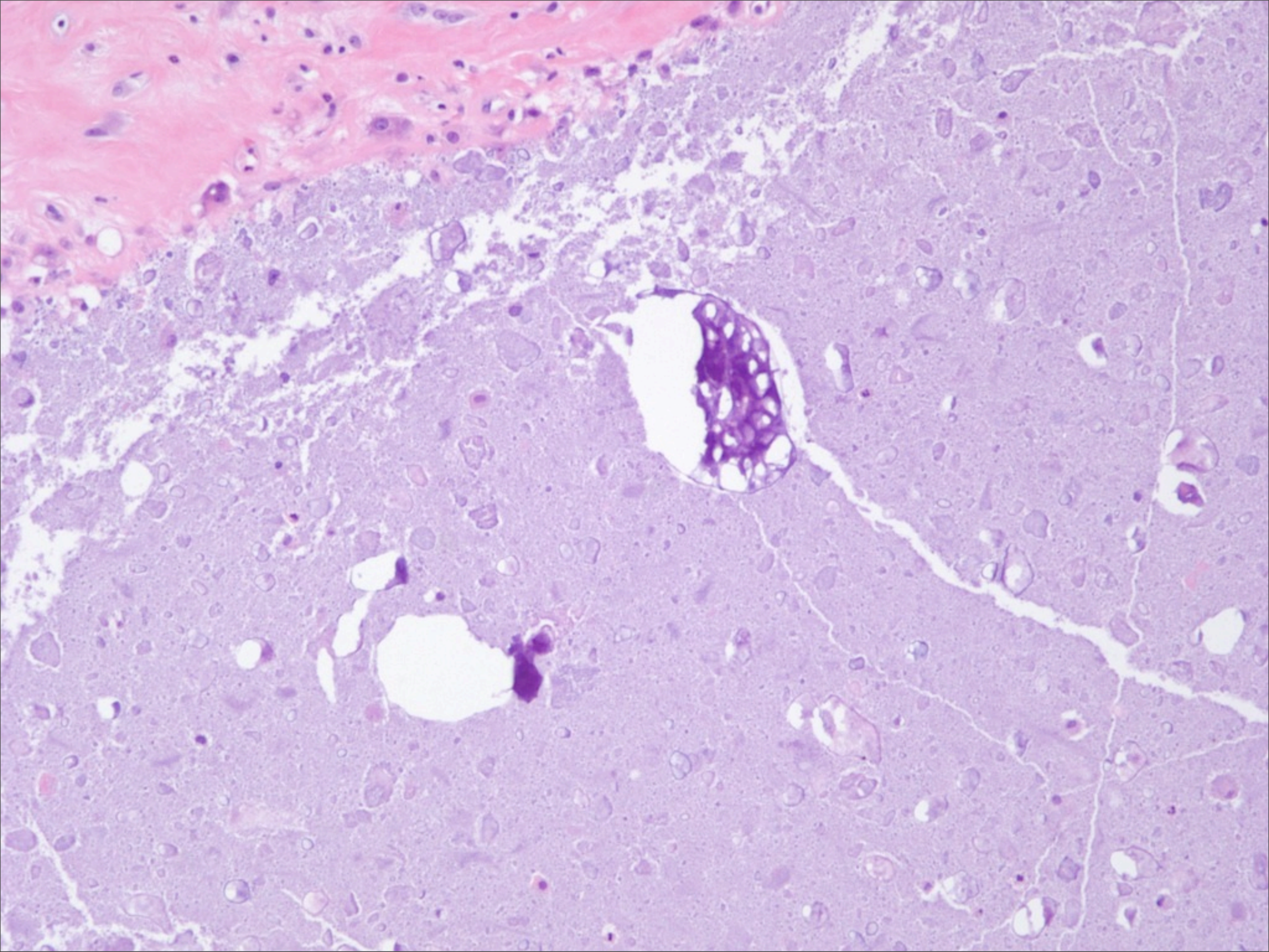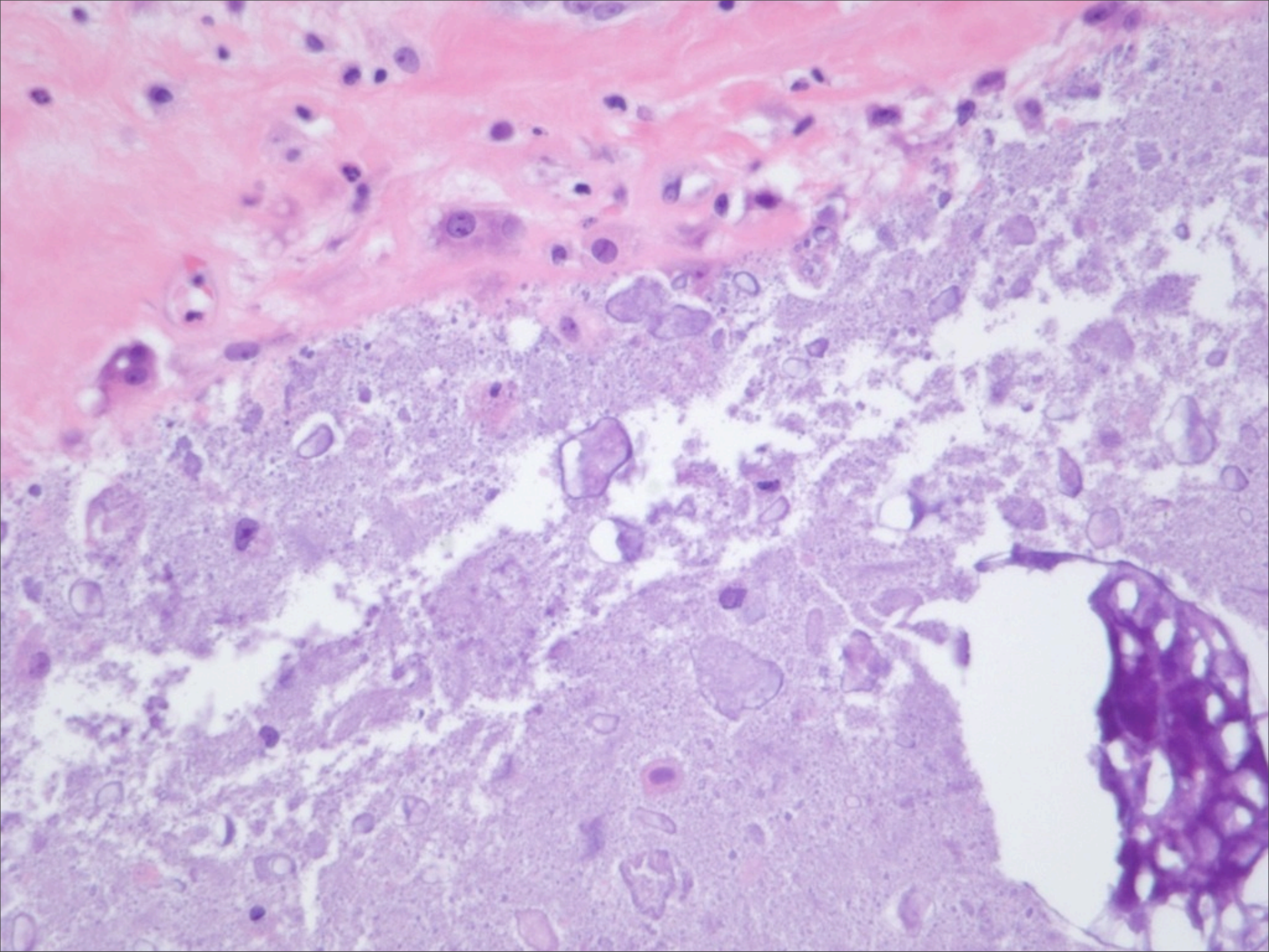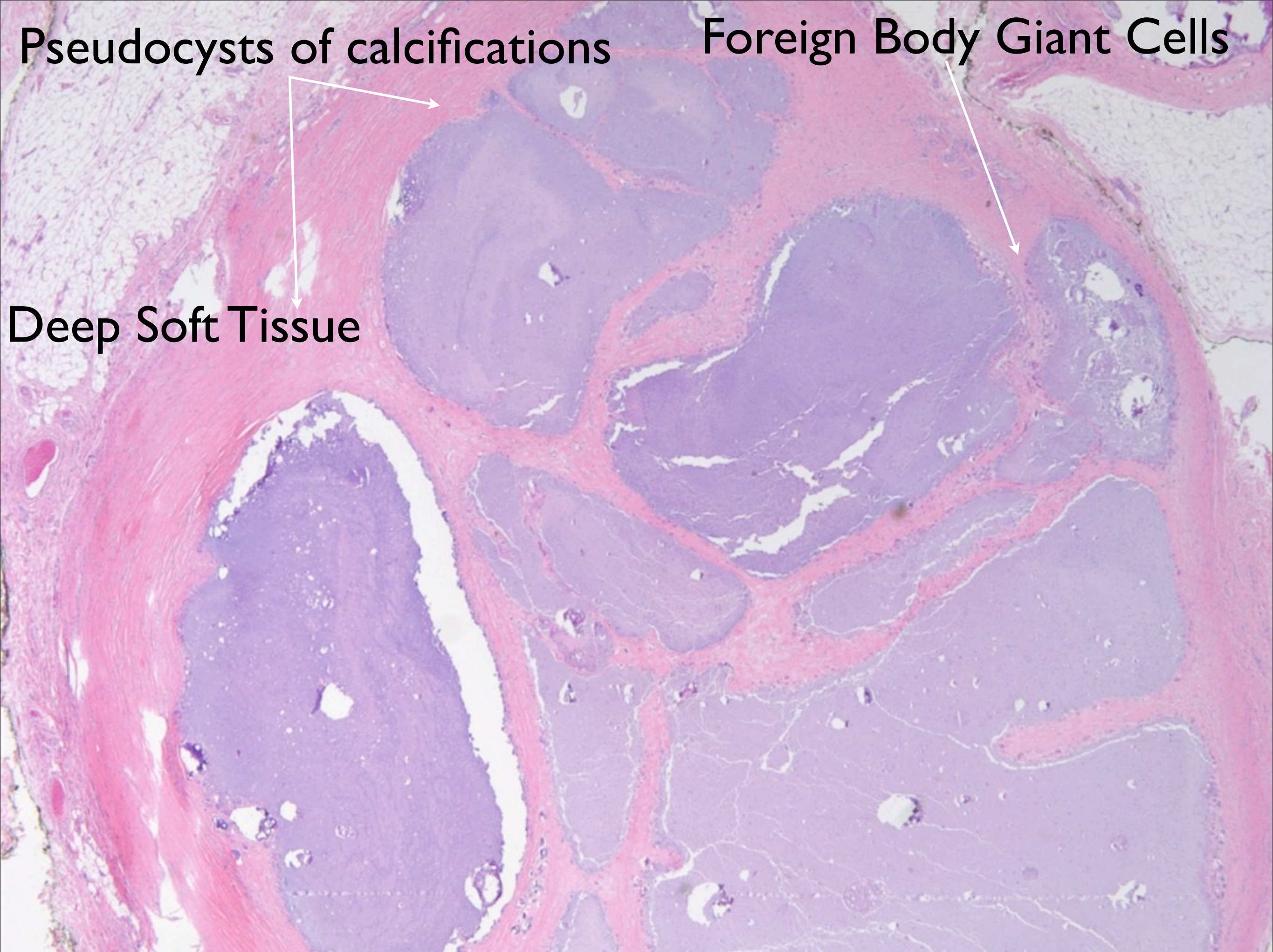


What is the best diagnosis?

- Epithelioid sarcoma
- Calcifying aponeurotic fibroma
- Osteoma cutis
- Pilomatricoma
- Tumoral calcinosis

Tumoral Calcinosis



Pseudocysts of calcifications

Foreign Body Giant Cells

Deep Soft Tissue